



# EQUINE DISEASE QUARTERLY

FUNDED BY UNDERWRITERS AT LLOYD'S, LONDON



APRIL 2017

Volume 26, Number 2

## COMMENTARY

### The Future of Parasite Control?

#### IN THIS ISSUE

##### Commentary

##### International

Fourth Quarter  
2016 ..... 2

##### National

Causes of Mortality... 3  
Parasite Control ..... 3

##### Kentucky

Nocardioform  
Placentitis ..... 4  
Equine Cardiac  
Disease ..... 5

In this issue, Dr. Gene Lyons provides a brief review of the history and current status of anthelmintic treatment of important equine gastrointestinal parasites. No new anthelmintics with newer modes of action have been introduced since the early 1980s, and levels of anthelmintic resistance are ever increasing in cyathostomin and *Parascaris* spp. parasites. While resistance is slow to develop, work by Dr. Lyons has clearly illustrated that once it appears in a given parasite, it is there to stay.

Today, we can expect resistance to at least one drug class to be present in every equine operation across the world, and an overwhelming majority will feature multi-drug resistance. With only three classes to choose between, we are running out of treatment options. A pertinent question to ask is how to tackle this emerging crisis and what to expect in the future.

The first step is to acknowledge the extent of the problem. Despite recommendations given during the past couple of decades, a majority of individuals in the industry continue to use old-fashioned parasite control programs based on frequent treatments given year-round without any consideration of treatment efficacy, parasites present, and climatic conditions. If no diagnostic testing is done, resistance will not be identified.

For the long term, we need new anthelmintic drug classes with new modes of action. It is important to learn from the past however, and realize that no drug class is going to remain effective indefinitely, and that reverting back to treatment regimens of the past would be a complete mistake. The pharmaceutical industry is not anticipating developing any equine products in the foreseeable future. Recent pharmaceutical trends are aimed at combination deworming products, *i.e.* formulations where two or more dewormers targeting the same parasites are combined into the same product. Research in the sheep industry has also

highlighted the importance of reducing treatment intensity to avoid development of multi-drug resistance. A recent project by the author highlighted the importance of high starting efficacy of the given combination. If combination treatment efficacy is markedly less than the desired 95 percent or above, resistance may develop quickly. The author's laboratory is also testing a bacterial dewormer. Strains of naturally occurring *Bacillus thuringiensis* produce crystal proteins capable of killing worm parasites. If successful, this could become an anthelmintic product in the future.

Perhaps the most important element in future parasite control programs is utilization of good diagnostic tools. Fecal egg counts will remain a cornerstone of control programs, but they have limitations in not providing information about larval stages and specific types (species) of parasites present. Recent collaborations have led to several new diagnostics, including species- and stage-specific serum ELISAs for important strongyle parasites, and an ultrasonographic technique for determining ascarid burdens in foals. One current project is making use of DNA-sequencing technologies to identify all parasite species present in a horse. Most recently, we have developed an automated smartphone-based fecal egg-counting system, which allows easier, quicker, and more precise fecal egg counts to be determined. Taking these diagnostic approaches collectively, the goal is to enable veterinarians and their equine clients to make more informed decisions about parasite control. The road to effective and sustainable parasite control is evidence-based, with veterinarians playing a central role.

#### Contact:

Martin K. Nielsen, DVM, PhD, DipEVP  
martin.nielsen@uky.edu  
(859) 218-1103  
Maxwell H. Gluck Equine Research Center  
University of Kentucky  
Lexington, KY

 University of  
Kentucky  
College of Agriculture,  
Food and Environment  
Department of  
Veterinary Science

LLOYD'S



## Fourth Quarter 2016

The International Collating Centre, Newmarket, United Kingdom, and other sources reported the following disease outbreaks.

Isolated cases of African horse sickness were recorded in South Africa, initially in Gauteng Province (October) and subsequently in the North West Province (December), both recognized as endemic areas for the disease.

Equine influenza was reported by the UK and the USA. The UK confirmed three outbreaks of the disease, two involving isolated cases in five-month-old foals and the third in a group of several unvaccinated horses. Outbreaks of influenza were recorded in four states in the USA, where the disease is considered endemic.

France, Germany, Ireland, Switzerland, and the USA reported multiple outbreaks of strangles during the period under review. The number of confirmed outbreaks included 12 in France, five in Germany, an estimated seven in Ireland, two in Switzerland, and 37 in the USA, where the disease is endemic. Many of the outbreaks involved single cases.

Equine herpesvirus 1 (EHV-1) related diseases were reported by France, Germany, Japan, the UK, and the USA. Respiratory disease was confirmed in France (four outbreaks), the UK (six cases on a premises on which several cases of neurologic disease also occurred), and the USA (widespread in various states).

Cases of EHV-1 abortion were diagnosed in France (single cases on two premises), Germany (one case), Japan (single cases on several premises, involving Thoroughbred or non-Thoroughbred mares), and the UK (single cases on two premises). EHV-1 related neurologic disease (myeloencephalopathy) was recorded in France (two outbreaks, one of which involved nine cases out of a group of 60 horses), Switzerland (a single case), the UK (two outbreaks, one involving an initial case and subsequently several additional cases), and the USA (two outbreaks, with one involving two cases on a high desert ranch and the other, six cases at an equestrian center).

Equine herpesvirus 4 respiratory disease was recorded in France (15 outbreaks, the majority represented by single cases of infection) and Switzerland (one outbreak involving four horses). The USA reported activity with equine herpesvirus 2 and/or 5 in a number of states, some associated with evidence of respiratory disease.

Equine infectious anemia was confirmed in Canada (single case in Saskatchewan), and the USA (single case in Utah). France and Switzerland reported cases of equine piroplasmosis. Piroplasmosis was considered endemic in France; Switzerland recorded only an isolated case of the disease.

A single case of equine coital exanthema (equine herpesvirus 3) was diagnosed in Kentucky, USA. Several cases of nocardioform placentitis were recorded in Kentucky, USA.

The USA reported outbreaks/individual cases of salmonellosis in a number of states, all of which related to infection with serogroup C1 *Salmonellae*.

A limited number of outbreaks of clostridial enteritis due to *Clostridium perfringens* Type A/ $\beta$ -2 toxin genotype, were confirmed in Kentucky, USA. Several cases of proliferative enteropathy (*Lawsonia intracellularis*) were recorded in Kentucky and Michigan, USA.

The fourth quarter of 2016 saw an additional 15 cases of Eastern equine encephalomyelitis confirmed in five states in the USA, nine of which were in Wisconsin. West Nile encephalitis was reported by Spain (nine cases) and the USA (20 cases involving six states of which 11 were in Oklahoma). The majority of cases in the USA were in unvaccinated horses.

The USA continues to record outbreaks of rhodococcal disease in numerous states; a limited number were reported in the period under review.

The fourth quarter of 2016 also saw recorded cases/outbreaks of several other diseases: ehrlichiosis in Switzerland (one outbreak), Getah virus infection in Japan (single case), and equine encephalosis (single case in the Western Cape Province of South Africa).



## Equine Disease Quarterly

## Editors

Peter Timoney  
Alan Loynachan  
Cynthia Gaskill

## Staff

Diane Furry  
Tawana Brown  
Dennis Duross

Correspondence should be addressed to the editors, Department of Veterinary Science, Maxwell H. Gluck Equine Research Center, University of Kentucky, Lexington, Kentucky USA, 40546-0099  
Telephone (859) 257-4757  
Fax (859) 257-8542

Internet address:  
<http://gluck.ca.uky.edu/equine-disease-quarterly>

Material published in the Quarterly is not subject to copyright. Permission is therefore granted to reproduce articles, although acknowledgment of the source and author is requested.

The University of Kentucky  
is an Equal Opportunity  
Organization.





## Causes of Mortality in Aged Horses in Kentucky

Over the last century, the place of the horse in society has shifted from that of an absolute necessity, primarily used for transportation and labor, to more of a pleasure animal. Today, horses are most commonly companion animals, lesson horses, breeding stock, and sporting competitors, with more limited use for farm and ranch work. This change in usage has resulted in an increasing geriatric horse population, and accordingly, the need to better understand the complexities of geriatric horse health.

The University of Kentucky Veterinary Diagnostic Laboratory (UKVDL) plays an important role in its support of Kentucky's horse industry. Between June 1, 2010, and June 30, 2012, one-hundred and thirteen horses aged fifteen years and older were submitted for necropsy to UKVDL. Review of these necropsy cases revealed that the main organ system contributing to the death of this group of aged horses was the digestive system, followed rather closely by the cardiovascular system.

Specific diagnoses of the digestive system that were noted in this group of geriatric horses included but were not limited to: strangulating lipoma; small intestinal entrapment, devitalization, and/or rupture; gastric rupture; large colon displacement, torsion, impaction and/or rupture; and necrotizing colitis of bacterial or unknown etiology.

Although prevention of these disorders is not generally possible, certain steps can be taken by owners to improve the digestive health of their horses. A consistent diet with sufficient roughage promotes a healthy digestive system for horses of all ages. However, as horses age, their teeth can wear unevenly and crack or break, preventing proper mastication and hindering the digestion of food. Therefore, proper dental care is crucial for older horses, along with appropriate nutritional substitutions for horses that can no longer chew forage adequately.

Maintaining an appropriate deworming regimen for horses of all ages can also go a long way to preventing digestive dysfunction. For example,

poorly-managed parasitic infections can contribute to the formation of adhesions, leading to intestinal obstruction, and tapeworm infection can lead to colic due to cecal impaction. Once an owner notices signs of colic and digestive distress, timely veterinary intervention can sometimes improve the outcome for a horse, particularly if corrective surgery is warranted by a specific diagnosis.

Death due to disease or dysfunction of the cardiovascular system may be somewhat unexpected. However, after delving more deeply into necropsy records, a not-so-surprising story emerged. Uterine artery rupture was responsible for approximately half of the cases where the main cause of death was attributed to the cardiovascular system. This statistic appears to be associated with the presence of numerous breeding farms in Central Kentucky. Increased risk of uterine artery rupture is an important issue for owners and veterinarians worldwide to consider when breeding mares over fifteen years of age. Additionally, the potential high risk for uterine artery rupture in older mares may highlight the option of embryo transfers to surrogate mares to obtain offspring from highly valued aged mares. As with any medical procedure however, embryo transfer and surrogacy are not without risk and may be restricted by certain breed registries.

While the main causes of death identified in this preliminary review for horses over the age of fifteen in Kentucky certainly highlight potential problem areas for the medical management of older horses, a more extensive review of past cases is needed to fully establish significant trends from this study.

**Contact:**

Ashton B. Miller, Graduate Research Assistant, in collaboration with Alan Loynachan, DVM, PhD and Amanda Adams, PhD  
ashton.miller@uky.edu  
(859) 257-4757  
Maxwell H. Gluck Equine Research Center  
University of Kentucky  
Lexington, KY

## Parasite Control: An Update

Internal parasites of horses have been recognized for centuries. Until the early 1900s, methods for the control of equine endoparasites lacked a scientific basis. For example, in the 1600s one

recommendation was to incise the horse's palate with the intent that the ingested blood would kill any internal parasites. Beginning in the 1940s and extending to the 1980s, new classes of antiparasitic

Figure 1. Nocardioform plac for 1991 to Feb 21, 2017, by foal

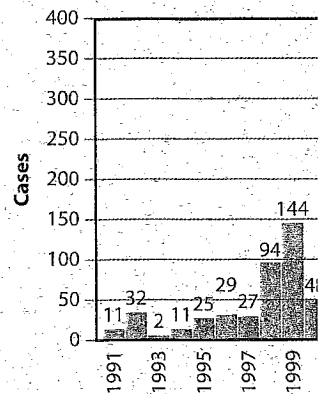
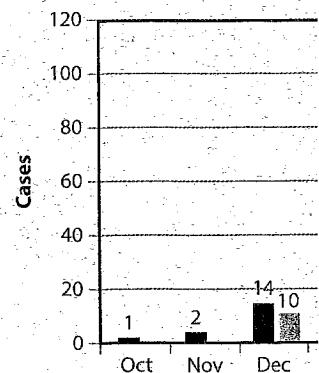


Figure 2. Nocardioform plac for 2011 and 2017 foaling st



compounds were developed approximately every 10 years. Currently in the USA, only benzimidazoles (fenbendazole and oxbendazole), tetrahydropyrimidines (pyrantel pamoate and pyrantel tartrate), and macrocyclic lactones (ivermectin and moxidectin alone or combined with praziquantel) are commercially available for parasite control in horses.

The major endoparasites of horses include bots, large strongyles, small strongyles or cyathostomes, ascarids, and tapeworms. Large strongyles (*Strongylus* spp.) are one of the most significant equine parasites. The larval stages can cause disease due to migration in blood vessels and abdominal organs. Drug resistance is not evident in the case of large strongyles. Cyathostome larvae do not migrate parenterally like *Strongylus* spp., but encyst in the mucosa and submucosa of the large intestine of the horse. Intestinal disease can be induced by cyathostomes when large numbers of larvae excyst from the lining of the large intestine, a condition called "larval cyathostomiasis." Resistance to fenbendazole, oxbendazole and pyrantel pamoate is now common among cyathostomes. Also, both ivermectin and moxidectin have become less effective against immature ( $L_4$ ) cyathostomes in the lumen of the large intestine; thus the life cycle is shortened. Heavy infections with adult ascarids (*Parascaris* spp.) can cause intestinal blockage and rupture because of their bulk. These too have become resistant to ivermectin, moxidectin, and pyrantel pamoate. The final group of equine endoparasites, tapeworms (*Anoplocephala* spp.), can also result in intestinal hypertrophy, blockage, intussusception, and rupture; they do not exhibit drug resistance.

Parasite treatment schedules have been based on the life cycle of the parasites since the early 1900s. In the mid-1960s, it was suggested that horses should be dewormed for strongyles every

six to eight weeks. This frequent deworming was thought 1) not to provide time needed for *Strongylus* spp. to mature, 2) to help decrease potential cyathostome egg deposition on pastures, and 3) not to allow time for ascarids to mature.

High strongyle fecal egg counts indicate contamination of pastures and increased potential for ingestion of infective larvae by grazing horses. Thus, profiling the number of eggs per gram (EPG) of feces has been used in updating deworming schedules. Since *Strongylus* spp. are now rarely encountered, a deworming schedule can be more flexible. Unfortunately, there is no direct relationship between EPG values and cyathostome numbers.

A suggested deworming program is as follows:

- Establish a strongyle EPG profile for individual horses rather than deworming all horses; a study of 1,114 Thoroughbred mares showed that one fecal sampling per horse was sufficient for establishing a strongyle EPG profile.
- For strongyles, use ivermectin or moxidectin alone or in combination with praziquantel twice a year—consider treating in the spring and fall. While benzimidazoles and pyrantel may be ineffective on cyathostomes, they may be efficacious in treating other parasite species.
- Treat foals every eight weeks of age for ascarid infection until they become yearlings; oxbendazole is currently considered the drug of choice followed by fenbendazole.
- Control *Strongyloides* with ivermectin or oxbendazole and tapeworms with praziquantel or pyrantel pamoate/tartrate.

**Contact:**

E.T. Lyons, PhD  
elyons1@uky.edu  
(859) 218-1115  
Maxwell H. Gluck Equine Research Center  
University of Kentucky  
Lexington, KY



KENTUCKY

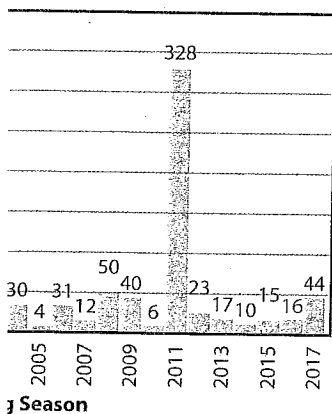
## Nocardioform Placentitis from an Epidemiological View

The outbreak of nocardioform placentitis in Kentucky's 2011 foal crop was concerning to the equine industry. While not on as large a scale as seen in 2011, we are seeing more cases of the disease in the 2017 foal crop in Kentucky than in the last several years (Figure 1).

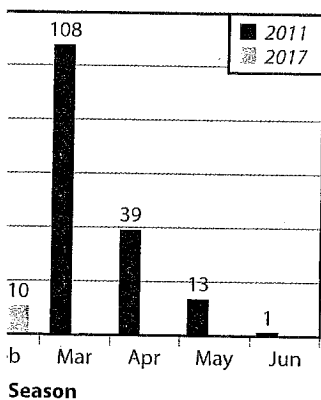
Nocardioform placentitis was first identified and characterized in the mid-1980s. Sequencing of the causative agents led to the term "nocardioform"

due to the phylogenetic relatedness of this large family of bacteria. The most common organisms have been identified as various *Amycolatopsis* and *Streptomyces* spp. and *Crossiella equi*. Outcomes from nocardioform placentitis can range from abortion, delivery of weak but viable foals, or delivery of normal foals; all outcomes are dependent upon the severity of the placentitis. In some cases, foals are not viable and are euthanized. In 2011, due to

cases seen at UKVDL from season.



cases seen at UKVDL by month



subsidies paid for placental submissions and examination, the response from the local equine industry was exceptional and the UKVDL witnessed the largest number of nocardioform placentitis cases submitted on record. The good news was that 70 percent of the 2011 cases resulted in viable foals.

Concerns of increased incidence of nocardioform placentitis in the 2017 foal crop surfaced in December 2016 with a local veterinarian indicating he was seeing an increase in cases. UKVDL pathologists and epidemiologists noticed an increase in cases submitted to the lab in January 2017 and alerted local practitioners and farm managers through listserv and social media.

Typically, nocardioform cases are first noted as early as October and run through May of any given year. The majority of cases are diagnosed from December through April, usually peaking in mid-March (Figure 2). Through the third week of February 2017, UKVDL has confirmed 44 cases of nocardioform placentitis. Of these 44 cases, 31 have resulted in abortion, 12 in viable foals, and in one case a live but non-viable foal.

The means of transmission is not yet identified. Nocardioform lesions are not similar to those of other types of bacterial placentitis or septicemic bacterial placentitis. Environmental factors are being investigated thoroughly and early analysis indicates an increase in nocardioform placentitis cases after a summer of hot, dry weather. Nocar-

dioform placentitis cases are almost always lower in years associated with a high incidence of leptospiral abortions, which is correlated with weather that is wetter than normal. Analysis of farms affected with nocardioform placentitis indicates larger farms with more pregnant mares and higher stocking densities are at greater risk. Preliminary data indicate that mares that spend more time in the barn are at risk of developing the disease; increased grazing times appear protective. There is a statistical indication that pre-breeding treatments with NSAIDs or progesterone could be protective, but this needs further study. Mares that are given post-breeding human chorionic gonadotropin (hCG) are at significantly lower risk, but this also requires further study.

Based on cases of nocardioform placentitis received by UKVDL from January 1, 2010; through February 21, 2017, there is little evidence that the disease recurs in particular mares. One exception is a mare that had a placenta submitted in 2011 that was positive for nocardioform and a fetus submitted in 2016 that also was diagnosed with the disease. The likelihood of recurrence of the disease in previously affected mares would appear extremely low.

**Contact:**

Jackie Smith, PhD, MSc, Dipl AVES

jsmit8@uky.edu

(859) 257-7559

University of Kentucky Veterinary Diagnostic Laboratory  
Lexington, KY

## Equine Cardiac Disease

Equine cardiac disease is an uncommon but potentially serious condition. Clinical signs range from poor performance to sudden death. Causes of cardiac disease in horses include congenital malformation, chronic valvular degeneration, cardiomyopathy, inflammatory or infectious disease, ruptured chordae tendineae, and cardiotoxins. This article describes common cardiotoxins that have been implicated in affecting horses in Central Kentucky.

Ionophores (e.g. monensin and lasalocid) are common feed additives and supplements intended for cattle, pigs, or chickens. Exposure occurs when horses have access to concentrated mineral pre-mixes containing ionophores formulated for cattle or through a feed-mixing error. Acute ionophore intoxication causes anorexia, muscle tremors, rapid heart rate, and respiratory distress due to heart failure. Chronic exposure results in unthriftiness, poor performance, exercise intolerance, rapid breathing, and sudden death from cardiac damage.

Blister beetles can be found in alfalfa hay, and are toxic to horses because they contain a highly irritating substance called cantharidin. Small amounts of cantharidin cause irritation to the gastrointestinal and urinary tracts. Moderate amounts cause cardiac muscle damage, low calcium, and synchronous diaphragmatic flutter ("thumps"). Large amounts cause shock and death within hours.

*Taxus* is a common cause of poisoning of horses in Central Kentucky. *Taxus*, or yew, is a popular evergreen ornamental shrub. Almost all parts of the plant, including the seeds, contain highly toxic compounds called taxines. In the winter, the concentration of taxines is at its highest within the plant. Even a small amount of plant material can cause rapid heart failure. Because taxines act so quickly, horses ingesting yew are often found dead without signs. When present, signs include weakness, incoordination, slow heart rate, and difficulty breathing.

## Equine Disease Quarterly Newsletter

Department of Veterinary Science  
Maxwell H. Gluck Equine Research Center  
University of Kentucky  
Lexington, Kentucky 40546-0099

Presorted Standard  
US Postage Paid  
Permit 51  
Lexington KY

*Address Service Requested*

7119 T21 P1 \*\*\*\*\*AUTO\*\*MIXED AADC 450  
WISCONSIN STATE HORSE COUNCIL  
PO BOX 72  
COLUMBUS WI 53925-0072

White snakeroot is a perennial woodlands plant common throughout the Eastern United States. White snakeroot contains a mixture of compounds called "tremetol." Intoxication is sporadic because the concentration of tremetol in the plant varies depending on location and prevailing growing conditions. Tremetol causes congestive heart failure and cardiac degeneration in horses. Tremetol can pass into the milk, poisoning nursing foals.

Rhododendrons, azaleas, laurels, mountain pieris, and fetterbush all contain grayanotoxins. Grayanotoxins cause either slow or rapid heart rate, abnormal rhythm, weak pulse, and cardiac arrest. These plants are particularly attractive in winter because their leaves remain green.

Milkweeds, or butterfly weeds, are wildflowers as well as cultivated ornamentals. Some milkweeds contain cardiotoxins called "cardenolides." Signs can begin within hours of plant ingestion and include slow or rapid heart rate, low blood pressure, and arrhythmias. Fresh cardiotoxic plants are generally unpalatable. They are more edible as clippings or baled with hay, but are no less toxic than fresh material.

Venomous snakes native to North America include the pit vipers—rattlesnakes, water moccasins, and copperheads. In Central Kentucky, timber rattlesnakes and copperheads are the most common. Most pit-viper venoms comprise dozens of different components; some of them as yet unidentified. Snakebites in horses most often occur on or near the muzzle and can result in severe swelling and edema. If the nasal passages become so swollen that labored breathing ensues, a tracheostomy may be necessary. Bleeding, tissue necrosis, and secondary bacterial infection around the bite wound are common sequelae. Some venoms contain cardiotoxins that damage the heart. Antivenins are available but must be administered in a timely manner, as they cannot reverse tissue damage that has already occurred.

Many other substances can be cardiotoxic, including a number of additional plants, medications (e.g. xylazine and theophylline), and illicit drugs (e.g. amphetamines and cocaine).

**Contact:**

Megan Romano, DVM  
Veterinary toxicology resident  
Megan.romano@uky.edu  
(859) 257-6777  
University of Kentucky Veterinary Diagnostic Laboratory  
Lexington, KY