



EQ GUINE DISEASE QUARTERLY

FUNDED BY UNDERWRITERS AT LLOYD'S, LONDON

OCTOBER 2018
Volume 27, Number 4



COMMENTARY

IN THIS ISSUE

Commentary

International

Second Quarter
2018 2

National

Asian Longhorned
Tick 3

Muscular Disorders
of Athletic Horses ... 4

Kentucky

Equine Renal
Disease 5

Vector or arthropod-borne diseases represent some of the most significant threats to human and animal health in certain regions/countries of the world. An ever-increasing number have spread beyond historically defined boundaries, in no small part as a result of continued expansion in international trade of live animals or animal products and because of global climate change. The worldwide spread of two human pathogens, Chikungunya and Zika viruses, from the African continent in recent years illustrates the major difficulties confronting the global community in containing these and other arthropod-borne diseases.

Within the realm of infectious diseases, it is more relevant in today's world to consider populations of humans and animals in different countries as co-existing in a global context, blurring the boundaries and reach of national political interests. We have in essence become an international community in which social media play a major role in communicating information across a spectrum of issues, including disease events.

Aside from what is known of the diversity and range of particular disease vectors in the USA, there is a need to be mindful of the possible introduction of a particular arthropod, e.g. tick or mosquito, that has never been recorded previously in the country—in other words, an invasive species. The article in this issue of the *Quarterly* on the discovery of the Asian longhorned tick (*Haemaphysalis longicornis*) for the first time in the USA highlights the challenges that can be presented by an invasive tick species. Although shown to be a competent vector of various diseases in a number of Pacific Rim countries, the potential competency of this particular tick to transmit animal or human diseases in the country remains to be established. Within recent months there have also been reports of the introduction of invasive species of

mosquito (*Ochlerotatus japonicus*) into Spain and of ticks (*Hyalomma marginatum* and *H. rufipes*) into Germany.

Although the discovery of *H. longicornis* was reported for the first time in 2018, subsequent investigations have shown that the tick had been in the USA at least since 2013. The lesson to be learned from this latest experience is that much greater surveillance and monitoring of tick and insect populations in general is needed to establish the range and distribution of the various species with potential to serve as competent vectors of known mosquito and tick-borne diseases of equids.

To better prepare ourselves for dealing with future disease threats, resources need to be made available to support the infrastructure for more comprehensive vector and disease surveillance programs in conjunction with improved capacity to respond to major disease events. The risk of such threats will increase inevitably with continued growth in the globalization of trade and the influence of climate change on our environment and the spread of vectors and vector-borne diseases.

An integral element to better prepare ourselves for the next disease threat is the need for greater awareness and better education of practicing veterinarians who are frequently the “first responders” in dealing with a case/outbreak of a novel disease or a possible invasive ecto-parasite. Increased public education and engagement is also important in addressing any disease threat that may evolve.

CONTACT:

Peter J. Timoney, MVB, MS, PhD, FRCVS
ptimoney@uky.edu
(859) 218-1094
Charles Issel, DVM, PhD
cissel@uky.edu
Maxwell H. Gluck Equine Research Center
University of Kentucky
Lexington, KY

 University of
Kentucky
College of Agriculture,
Food and Environment
Department of
Veterinary Science

LLOYD'S



INTERNATIONAL

Second Quarter, 2018

The International Collating Centre, Newmarket, United Kingdom, and other sources reported the following equine disease outbreaks.

The Republic of South Africa (RSA) reported outbreaks of African horse sickness in most provinces in the country with the exception of the Western Cape. One outbreak was recorded in Swaziland.

Argentina, the UK, Uruguay, and the USA reported outbreaks of equine influenza. At least 42 cases were confirmed on 10 premises located in five provinces in Argentina. Three-year-old horses were principally affected. The strain involved belonged to clade 1, Florida sublineage of H3N8 virus. The UK and Uruguay recorded single outbreaks of the disease. Equine influenza was reported as endemic in the USA, occurring in four states, with multiple outbreaks in one state.

Germany, Ireland, Switzerland, the UK and the USA recorded strangles. The number of outbreaks included six in Germany, outbreaks in all four provinces in Ireland and eight in Switzerland. The UK and the USA stated that the disease was endemic in their respective countries. More than 85 outbreaks involving 178 cases were recorded in 24 states in the USA.

Equine herpesvirus 1 (EHV-1) infection was reported by Belgium, Denmark, France, Germany, Greece, Ireland, Japan, RSA, Switzerland, the UK, and the USA. Infection associated with fever was diagnosed in three states in the USA. Respiratory disease was confirmed in Belgium (10 outbreaks), France (seven outbreaks), Germany (one case), Switzerland (one outbreak), the UK (one outbreak) and the USA (widespread in various states). EHV-1 abortion was recorded in Denmark (one case), France (eight cases), Germany (12 cases), Japan (nine cases involving seven premises), RSA (two cases), the UK (five cases of which three were on one premises), and the USA (two cases).

EHV-1 related disease in neonatal foals was diagnosed in France (one case) and the UK (two cases).

EHV-1 associated neurologic disease was reported from Denmark (two cases), France (four cases), Germany (one case), Ireland (two cases), and the USA (10 outbreaks in eight states; all but one involved single cases of the disease).

Equine herpesvirus 4 (EHV-4) respiratory disease was recorded in Argentina (four outbreaks), Belgium (one outbreak), France (59 outbreaks), Germany, RSA and Switzerland (each confirmed single cases of the disease), and the UK (four outbreaks). France and Germany reported single cases of EHV-4 abortion.

The USA recorded multiple cases of equine herpesvirus 2 and/or 5 infection in several states, some associated with a history of respiratory disease.

Equine infectious anemia was reported from Canada (single cases on two premises), Germany (one case), Greece (one case), and the USA (18 cases involving six states; 12 cases were in Texas).

RSA reported that equine piroplasmiasis was widely present in the country with multiple cases of the disease confirmed in five provinces.

Germany confirmed *Taylorella equigenitalis*, the causal agent of contagious equine metritis in eight stallions and one mare, all of the Icelandic breed. Seven premises were involved.

Single cases of equine coital exanthema caused by equine herpesvirus 3 were recorded by Switzerland and the USA.

Cases of salmonellosis were reported from Ireland (one case) and the USA (12 cases, the majority associated with strains of salmonella belonging to serogroup B). The USA confirmed three cases of equine neorickettsiosis (Potomac horse fever), and Germany one case of rotaviral diarrhea in a foal.

A single case of rabies was confirmed in Nebraska, USA.

The USA recorded 10 cases of Eastern equine encephalomyelitis, all in Florida.

Single cases of West Nile encephalitis were reported from Brazil and RSA.

RSA also recorded 16 cases of encephalitis due to Middleburg virus infection and two cases due to Shuni virus infection.

Equine encephalosis was reported from RSA. Thirty-three cases were diagnosed in five provinces; these included seven in the Western Cape Province.

Rhodococcus equi infection is endemic in the USA; 14 cases were confirmed during the period under review.

Germany reported a case of anaplasmosis and Switzerland four cases of ehrlichiosis.



Equine Disease Quarterly

Editors

Peter Timoney
Alain Loynachan
Cynthia Gaskill

Staff

Diane Furry
Tawana Brown
Dennis Duross
Anita Fleming

Correspondence should be addressed to the editors, Department of Veterinary Science, Maxwell H. Gluck Equine Research Center, University of Kentucky, Lexington, Kentucky USA, 40546-0099. Telephone (859) 257-4757. Fax (859) 257-8542.

Internet address:
<http://gluck.ca.uky.edu/equine-disease-quarterly>

Material published in the Quarterly is not subject to copyright. Permission is therefore granted to reproduce articles, although acknowledgment of the source and author is requested.

The University of Kentucky is an Equal Opportunity Organization.



Printed on recycled paper



NATIONAL

Asian Longhorned Tick (*Haemaphysalis longicornis*): Challenges from an Invasive Ixodid Tick

Asian longhorned ticks (ALT) have small, reddish-brown bodies with no distinctive markings to facilitate quick recognition. In addition, unfed adults are smaller (3 to 4 mm long) than the familiar commonly encountered hard ticks. The initial confirmed identification of ALT in the USA was based on specimens collected from a heavily-infested sheep in New Jersey in 2017. This was thought to be the first detection of a new tick species in the USA in 50 years. However, subsequent investigation revealed that specimens removed from a dog in New Jersey in 2013, which were initially identified as the native rabbit tick *Haemaphysalis leporispalustris*, were also ALT. Consequently, the species has been present for several years and has spread. As of August 2018, this invasive tick has been found in at least one location in Arkansas, Connecticut, Maryland, New Jersey, New York, North Carolina, Pennsylvania, Virginia, and West Virginia (Figure 1). Reported hosts have included cattle, a dog, a horse, an opossum, and white-tailed deer.

Native to China, Korea, and Japan, the ALT became established in Australia and New Zealand, where it feeds on a variety of wild and domestic animals and humans. This species does best in moist, warm environments. However, it can withstand temperatures from its developmental threshold of -12°C to a lethal high temperature of 40°C . Adults and particularly larval stages of the species appear to have a relatively low tolerance of dehydration, which may play an important role in its ultimate distribution in the USA.

The ALT is a three-host tick with a life cycle that takes about a year. While males and females occur in approximately equal numbers over its

native habitat, very few males have been found in the USA. Apparently, parthenogenesis (female reproduction without the need of fertilization by a male) is a significant feature of its biology in the USA (Figure 2). Females can deposit about 2,000 eggs, all female, so local populations can grow rapidly following establishment. This can result in significant blood loss and stress to infested hosts. While the initial introduction(s) of this tick is unknown, genetic mapping has identified three mitochondrial DNA lineages. This points to at least three distinct female lineages. Parthenogenesis would allow relatively rapid selection for biotypes in response to environmental factors in its new habitat.

Collections of ALT from sheep in China indicate the ears and periocular areas are preferred attachment sites. Specimens collected and tested in the USA have not been shown to carry any diseases, but ALT are competent disease vectors in Asia contributing to theileriosis and babesiosis in cattle in Australia and New Zealand and anaplasmosis in Korea. Severe fever with thrombocytopenia syndrome (SFTS) is an emerging hemorrhagic fever in East Asia caused by SFTS virus (SFTSV), a newly discovered phlebovirus. The *Haemaphysalis longicornis* tick has been suspected to be the vector of SFTSV. Time will tell the story of its vector potential in North America. Preserved specimens of suspected Asian longhorned ticks should be sent to the National Veterinary Services Laboratories in Ames, Iowa for identification.

CONTACT:

Lee Townsend, MS, PhD
ltownsen@uky.edu
(859) 257-7455
Department of Entomology
University of Kentucky
Lexington, KY

3

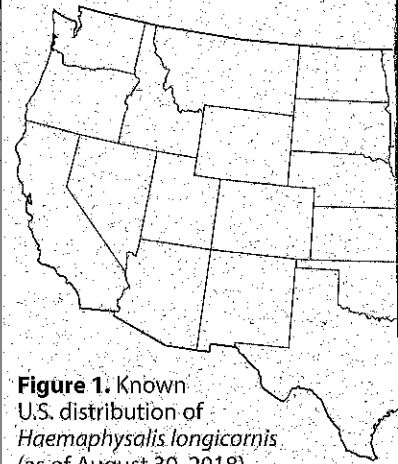


Figure 1. Known U.S. distribution of *Haemaphysalis longicornis* (as of August 30, 2018).



Figure 2. The female Asian longhorned (*longicornis*) is able to reproduce without local populations after establishment. eggs, all female. Male ALT in the United States. Photo by Dr. David S. Gathany, Centers for Disease Control and Prevention.

The equine muscular system is the engine room of the horse, comprising over half of the body mass of Thoroughbreds. At the cellular level it is a complex system, comprised of a vast array of specialized proteins that coordinate functions ranging from power output to heat management. Disorders of the muscular system cause poor performance and in some cases, death; yet in certain groups of athletic horses, 5% to 25% of individuals have heritable muscular disorders. Muscle disorders are very common in athletic horse breeds because, surprisingly, they can also provide some beneficial effects, ranging from enhanced muscle mass to economic metabolism.

Given the importance of the muscular system to athletic performance of the horse, not surprisingly, it has attracted considerable research focus. In the past two decades, "tying-up" in athletic horses has been teased into at least three distinct disorders, which are heritable and therefore tend to have strong breed predispositions. Several other heritable muscular disorders of horses have also been defined, causing problems ranging from profound weakness to respiratory paralysis and early neonatal death. Advances in medicine now permit convenient hair or blood tests for many of these diseases due to their genetic basis, and breeders are encouraged to display appropriate stewardship by testing their breeding stock for known disorders that have scientifically validated genetic tests available. Current research efforts are attempting to identify the genetic signature of the disease causing tying-up in Thoroughbreds and Standardbreds, which has proved challenging, and the disease causing tying-up in Arabian horses. Advanced molecular techniques are also being applied to some disorders to determine exactly what goes wrong at the cellular level, to help define the basis of clinical signs and to better direct the development of effective genetic tests.

Currently, the most clearly defined muscular disorders of athletic breeds are polysaccharide storage myopathy (PSSM), hyperkalemic periodic paralysis (HYPP), and glycogen branching enzyme deficiency (GBED), because the cellular nature of these diseases and the underlying causative genetic mutations are largely defined. PSSM is common in Quarter horses and related breeds, and typically


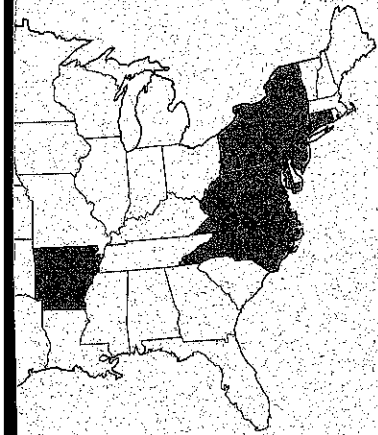
causes signs of tying-up. It is also linked to high body condition, which can be desirable in those breeds. HYPP causes weakness and paralysis and, occasionally, death. It is also associated with high muscle mass, and therefore became prevalent due to positive selection pressure for this trait. GBED is an inevitably fatal disorder of Quarter Horses and Paints, causing weakness and death in the first days to weeks of life. It is uncommon, and association with a positive trait is not recognized. All three of these disorders can be readily tested for on hair or blood.

Standardbred and Thoroughbred horses appear to share a disorder causing tying-up during training, with clinical signs rarely or never seen during actual racing exercise. This disease is referred to as recurrent exertional rhabdomyolysis (RER). It appears to be more common in faster horses because it might permit more rapid muscular processes at the cellular level, hence there has been positive selection pressure on this disease. The genetics of RER have proven frustrating to define despite many years of work. Warmblood and Arabian horses might also share a disorder recently coined as "myofibrillar myopathy" (MFM). Signs of this disease appear to consist of tying-up in Arabian horses, and poor performance and poorly defined movement abnormalities in Warmblood horses. The genetic cause of MFM is not known and no scientifically validated genetic tests exist for MFM or RER.

In summary, muscular disorders are common in athletic horses, and can be frustrating and even fatal under some circumstances. Association with specific positive traits has contributed to the prevalence of some of these diseases. Genetic testing is available for many heritable equine diseases, and it is likely that testing for less clearly defined disorders will be developed in the coming years. Genetic stewardship relies on breeders being educated about heritable disorders, and performing proactive breeding selection processes to produce horses that are not only high performers but also genetically sound.

CONTACT:

Erica McKenzie, BSc, BVMS, PhD, DACVIM, DACVSMR
 erica.mckenzie@oregonstate.edu
 (541) 737-2858
 Carlson College of Veterinary Medicine
 Oregon State University
 Corvallis, OR



and tick (ALT) (*Haemaphysalis*) at male fertilization to rapidly grow. ALT are able to deposit about 2,000 eggs. ALT are rare. Source: James and Prevention



KENTUCKY

Equine Renal Disease

Renal function is an important component of overall health in any species. The kidneys perform several important functions, including waste removal, electrolyte balance, blood pressure maintenance, a calcium source for bone health and production of factors for red blood cell stimulation, to name a few. In addition, the kidneys receive substantial blood flow—approximately 25% of the cardiac output. Therefore, changes in blood flow, either increased or decreased, can have a significant impact on renal health.

Equine necropsy cases submitted to the University of Kentucky Veterinary Diagnostic Laboratory (UKVDL) over an eight-year period (2010-2018) were queried for diagnoses related to renal pathology. Equine fetuses, foals, and adults of a variety of breeds were included. It was determined that 3.6% (386/10,541) of equine submissions had some type of renal pathology. Of those diagnoses, renal lesions were determined to be primary in 38% of cases (n=148), secondary to another process in 55% of cases (n=211), or incidental in 7% of cases (n=27).

Significant processes associated with primary lesions included: inflammatory/infectious (95 cases); congenital (21 cases); neoplastic renal carcinoma/adenocarcinoma (10 cases); nephroliths (10 cases); toxic (four cases); trauma (one case); and other miscellaneous (i.e. chronic renal failure, protein losing nephropathy) conditions (seven cases).

Within the infectious/inflammatory group, the most common cause was a bacterial pathogen resulting in nephritis. The largest proportion of cases was due to *Leptospira interrogans* infections in fetuses. Leptospirosis is a cause of abortion that often localizes to the kidney. *Actinobacillus equuli* was another common bacterial isolate, most often seen in neonatal foals and occasionally adults. In foals, infection with *A. equuli* is colloquially termed “sleepy foal disease.” Routes of infection for *A. equuli* include a contaminated umbilicus, inhalation or ingestion. Several cases of bacterial pyelonephritis were identified. Pyelonephritis is inflammation of the renal pelvis that most often results from an infection that extends up to the kidneys from the lower urinary tract (i.e. urinary bladder). The most common bacterial isolates identified from cases at the UKVDL included

Streptococcus zooepidemicus, *Escherichia coli*, and *Enterococcus* sp.

Lesions that comprised the congenital category included renal dysplasia, renal agenesis, congenital renal cysts or congenital hydronephrosis/hydro-ureter. While there have been proposed associations of hereditary or nutritional components for developmental renal abnormalities in some species (i.e. dogs and pigs), in horses the pathogenesis of these congenital lesions remains to be elucidated.

Significant nephroliths (kidney stones) were identified in 10 horses. The stones were composed of calcium carbonate or a mixture of calcium carbonate with other minerals. Typically, horses with nephroliths remain asymptomatic until the stone results in obstruction. Development of nephroliths has been associated with any nidus of renal disease including cysts, papillary necrosis, pyelonephritis or neoplasia.

Papillary (medullary crest) necrosis due to suspected long-term use of non-steroidal anti-inflammatory drugs (NSAIDs) was identified in three of the four cases in the toxic category. NSAIDs (i.e. phenylbutazone/bute and flunixin meglumine/Banamine) are routinely used in horses for pain management. NSAIDs work by inhibiting a specific group of enzymes, cyclooxygenase (COX), which subsequently reduces inflammation. Unfortunately, other downstream effects of this pathway include decreased production of prostaglandins. Specific cells located in the renal medulla produce prostaglandins that are mediators of blood flow to the tissue. Therefore, decreased prostaglandin production results in impaired blood flow to the medulla and subsequent necrosis. Other compounding factors include dehydration and use of multiple NSAIDs. Luckily, renal complications due to NSAIDs are well described with the result that there is judicious use of these medications in practice.

The equine kidney has a vital role in overall health. A variety of disease processes can impair renal function. Awareness of these diseases is important for equine health.

CONTACT:

Jennifer Janes, DVM, PhD
 jennifer.janes@uky.edu
 (859) 257-8283
 University of Kentucky Veterinary Diagnostic Laboratory
 Lexington, KY